

SHOULDER HEMIARTHROPLASTY WITH NONPROSTHETIC GLENOID ARTHROPLASTY

The Ream-and-Run Procedure

Frederick A. Matsen III, MD

Bradley C. Carofino, MD

Andrew Green, MD

Samer S. Hasan, MD, PhD

Jason E. Hsu, MD

Mark D. Lazarus, MD

Matthew D. McElvany, MD, MAS

Michael J. Moskal, MD

I. Moby Parsons IV, MD

Matthew D. Saltzman, MD

Winston J. Warme, MD

*Investigation performed at the
Department of Orthopaedics and
Sports Medicine, University of
Washington, Seattle, Washington*

Abstract

» Glenoid component wear and loosening are the principal failure modes of anatomic total shoulder arthroplasty (aTSA).

» The ream-and-run (RnR) procedure is an alternative glenohumeral arthroplasty for patients who wish to avoid the risks and limitations of a prosthetic glenoid component.

» During the RnR procedure, the arthritic glenoid is conservatively reamed to a single concavity, while the prosthetic humeral component and soft tissues are balanced to provide both mobility and stability of the joint.

» The success of the RnR procedure depends on careful patient selection, preoperative education and engagement, optimal surgical technique, targeted rehabilitation, and close postoperative communication between the surgeon and the patient.

» While the RnR procedure allows high levels of shoulder function in most patients, the recovery can be longer and more arduous than with aTSA.

» Patients who have undergone an RnR procedure occasionally require a second closed or open procedure to address refractory shoulder stiffness, infection, or persistent glenoid-sided pain. These second procedures are more common after the RnR than with aTSA.

Wear and loosening of the glenoid component are the principal causes of failure after anatomic total shoulder arthroplasty (aTSA), especially in young and active patients¹⁻¹². The ream-and-run (RnR) procedure is a method for managing glenohumeral arthritis in patients who wish to avoid the risks of implant wear and loosening as well as surgeon-imposed activity limitations on heavy or impact loading that are associated

with a prosthetic glenoid component¹³⁻¹⁵. This article reflects the experience of 11 shoulder surgeons from across the United States who currently employ the RnR procedure in their practices. These surgeons formed a study group that focuses on enhancing the understanding, technique, and outcomes of the procedure.

The RnR glenohumeral arthroplasty differs from a humeral hemiarthroplasty (HHA), which is performed without attention to the arthritic

Disclosure: The Disclosure of Potential Conflicts of Interest forms are provided with the online version of the article (<http://links.lww.com/JBJSREV/A738>).

This is an open-access article distributed under the terms of the [Creative Commons Attribution-Non Commercial-No Derivatives License 4.0](https://creativecommons.org/licenses/by-nc-nd/4.0/) (CCBY-NC-ND), where it is permissible to download and share the work provided it is properly cited. The work cannot be changed in any way or used commercially without permission from the journal.

COPYRIGHT © 2021 THE
AUTHORS. PUBLISHED BY THE
JOURNAL OF BONE AND JOINT
SURGERY, INCORPORATED. ALL
RIGHTS RESERVED.

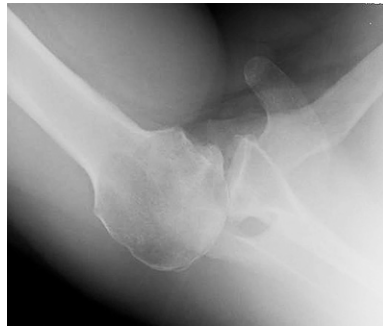

Fig. 1-A

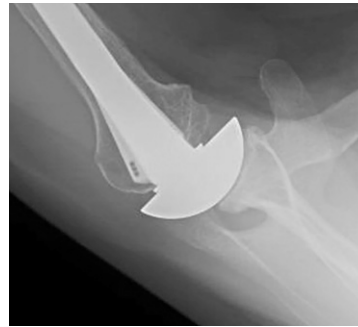

Fig. 1-B

Figs. 1-A and 1-B Preoperative and postoperative anatomy. **Fig. 1-A** Preoperative glenohumeral pathoanatomy. A posteriorly biconcave glenoid with severe posterior decentering seen on the axillary truth view¹⁹ in a 40-year-old active male patient. A humeral hemiarthroplasty without addressing this glenoid pathology would result in persistent posterior decentering, with increased joint pressure on the posterior glenoid and continued posterior glenoid wear. In the ream-and-run procedure, the arthritic glenoid is conservatively reamed to a single concavity. The joint pressure is reduced by distributing the humeral force across a broadened contact area. This figure shows the axillary view of the same patient shown in Figure 1-A at 5 years after the RnR procedure. In this case, an anteriorly eccentric humeral head was used to help recenter the humeral head on the reamed glenoid. Note the radiographic joint space between the humeral head prosthesis and the reamed glenoid.

glenoid. It differs from a TSA in that it enables patients to safely pursue substantially greater levels of shoulder function than those recommended after a TSA. However, the recovery from the RnR procedure may be longer and more challenging¹⁶. The collective experience derived from this study group demonstrates the unique aspects of the RnR, emphasizing the importance of a holistic approach spanning the entire episode of care.

Rationale

Normal shoulder function is a balance of mobility and stability (Video 1). Dynamic stability of the glenohumeral joint depends largely on concavity compression, (i.e., the containment of the forces acting on the humeral head within the glenoid concavity)^{17,18}. In glenohumeral osteoarthritis, the stabilizing monoconcave shape of the normal glenoid surface is altered by pathologic wear, becoming flattened or biconcave with increased glenoid retroversion and humeral head decentering on the glenoid face^{19,20}. These changes compromise the stabilizing function of the glenoid and diminish the contact area for glenohumeral load distribution (Fig. 1-A). Whereas an isolated HHA does not address these pathologic changes in glenoid surface

shape, the RnR provides a method for managing the arthritic glenoid by reaming it to a single stabilizing concavity and balancing the soft tissues to center the prosthetic humeral head on the reamed glenoid²¹ (Fig. 1-B).

Considerations in Patient Selection

Because the recovery after an RnR can be longer and more challenging, it is important that patients considering this procedure are well-informed, resilient, and highly motivated²²⁻²⁵. Patients must understand that the procedure sets the stage for them to pursue their desired level of function, but a good recovery requires them to fully commit to the process. Those seeking the quickest path to a comfortable shoulder with an easier rehabilitation may be better served by a TSA.

While younger, active patients are often ideal candidates for the RnR procedure, age is not a major consideration; the RnR is successfully performed in individuals from 20 to 80 years of age who desire high levels of activity. Carefully selected female patients can do well after the RnR procedure; however, on average, the outcomes in women are not as good as those in men^{26,27}. Other patient factors that are associated with suboptimal outcomes include narcotic use, tobacco

use, depression, medical comorbidities, cardiovascular conditions that require anticoagulants, dystonic conditions such as Parkinson disease, prior surgery, and Workers' Compensation insurance.

Glenoid wear, retroversion, and biconcavity, as well as posterior decentering of the humeral head on the glenoid, are not contraindications for the RnR procedure. Because these features are associated with higher glenoid component failure rates after a TSA^{28,29}, their presence may actually favor the RnR^{27,30}. Shoulders with a compromised rotator cuff tend to have inferior results after the RnR procedure. Patients with weakened glenoid bone from inflammatory arthropathy, osteoporosis, or chondrolysis may fail to develop a durable articular surface after glenoid reaming and may be better managed with a TSA.

Setting the Patient Up for Success

The process of optimizing a patient's outcome after the RnR procedure must begin well before surgery. Critical to success is establishing a close surgeon-patient relationship that provides assurance, coaching, structured support, and ready access to the surgeon's team throughout a potentially protracted recovery. Printed handouts

and web-based information describing the procedure and recovery program can provide important supportive resources. Prior to surgery, instruction regarding the necessary exercises provides a platform for rehabilitation after the procedure.

Patients must embrace the importance of being optimistic, healthy, well-nourished, and well-hydrated, with no exposure to nicotine for 3 months prior to surgery. Individuals with diabetes should have excellent control of their blood glucose levels. Anti-inflammatory drugs and anticoagulants should be managed to minimize the risk of a postoperative wound hematoma.

Informed consent should include a frank discussion of the fact that the RnR is an elective procedure; alternatives include nonoperative management and aTSA; there is a risk of stiffness, persistent pain, infection, and a recovery process that may extend up to 2 years; and manipulation under anesthesia (MUA) or revision surgery may be needed postoperatively and that second procedures are more common after the RnR than with aTSA. Patients are pro-

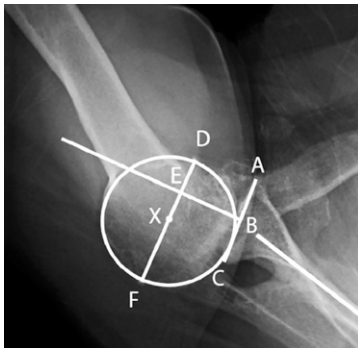


Fig. 2

Measuring glenoid version and humeral head decentering. An axillary truth view with the arm in a functional position of elevation in the plane of the scapula enables the measurement of glenoid version and humeral head decentering both before and after surgery. The glenoid version is the angle between lines AC and B. The posterior decentering percentage is $100\% \times EX/DF$. Line segment AC connects the anterior and posterior edges of the glenoid. Line B indicates the plane of the scapula. A circle is fit to the humeral articular surface with its center at point X. Line segment DF is a diameter of the circle drawn parallel to AC. Point E is the intersection of the perpendicular bisector of AC and DF.

vided with published data as well as the surgeon's personal experience with the RnR procedure.

Preoperative decentering can be assessed on the so-called "axillary truth view" radiograph or the computed tomography (CT) scan as the percent of the humeral head that lies behind the perpendicular bisector of a line segment connecting the anterior and posterior edges of the glenoid^{19,31} (Fig. 2). Often, posterior decentering is more apparent on an axillary view that is made with the arm in a functional position of elevation rather than on a CT scan that is made with the arm at the side. Preoperative imaging may underestimate the posterior instability that is subsequently observed at surgery after osteophytes have been removed and soft-tissue adhesions and contractures have been released. In the past, concern for posterior instability after the RnR procedure led surgeons to use thicker humeral head components with overstuffing of the joint, which resulted in limitation of the range of motion³². Currently, however, surgeons are gaining confidence in methods for managing potential instability without compromising range of motion.

Perioperative Management

Patients desiring the RnR procedure have specific demographics that are associated with an increased risk of Cutibacterium periprosthetic joint infection (CPJI) (i.e., young, healthy men with low American Society of Anesthesiologists [ASA] scores, low body mass index, supplemental testosterone use, and prior shoulder surgery)^{33,34}. These patients have higher levels of Cutibacterium in their dermal pilosebaceous glands, which is a potential source of wound and implant contamination³⁵.

No preoperative washes or surgical skin preparation can eliminate Cutibacterium from these dermal glands or prevent it from entering the surgical field^{36,37}. Approaches for mitigating the risk of CPJI may include preoperative

intravenous ceftriaxone and/or vancomycin, thorough skin preparation, the discarding of instruments that have been used in the superficial tissues, frequent wound irrigation, the use of povidone-iodine or other antiseptic lavage, preventing contact between the humeral implants and the skin, and topical antibiotics. In high-risk patients, a course of postoperative oral antibiotics (e.g., a 3-week course of doxycycline or amoxicillin-clavulanate) may be considered.

Postoperative hematomas can increase discomfort and interfere with motion. Bleeding can be minimized by meticulous hemostasis, intravenous or topical tranexamic acid, and topical thrombin. Drains are usually avoided because they can provide an avenue for introduction of Cutibacterium from the skin into the joint.

Surgical Technique

The rationale for the RnR procedure and the surgical technique^{38,39} is demonstrated in 2 videos (Video 1 and the video accessed through the *Video Journal of Orthopaedics*⁴⁰).

Subscapularis Management

Careful takedown, release, and secure repair of the subscapularis tendon is essential in the RnR procedure because early motion exercises must be started before healing is complete and a secure subscapularis is important for high levels of shoulder function. Whether a peel, a tenotomy, or a lesser tuberosity osteotomy is used, the repair must be carefully examined and noted to be solid before wound closure.

Glenoid Exposure

Glenoid exposure may be challenging in patients who undergo the RnR procedure, especially if they are muscular, have a retroverted biconcave glenoid, and/or have had prior surgery. Exposure can be optimized by:

1. Locating the skin incision over the deltopectoral interval starting near the clavicle;

2. Releasing the anterior and inferior capsule from the glenoid and the labrum. Some surgeons preserve the labrum to optimize load-sharing and stability;
3. Flexing the shoulder to relax the deltoid and pectoralis muscles;
4. If necessary, removing bone from the inferior one-third of the lesser tuberosity area, providing reamer access without compromising subscapularis repair to the superior two-thirds of the lesser tuberosity; and
5. Removing retractors during reaming so that they do not interfere with reamer positioning.

Glenoid Reaming

The objective of glenoid reaming is to create a single concavity with a congruent surface that helps recenter the humeral head and optimizes load distribution on the glenoid⁴¹. The preservation of subchondral bone is critical to prevent additional glenoid wear; therefore, surgeons are inclined to accept glenoid retroversion rather than reaming

aggressively in an attempt to modify version.

The essential elements of reaming are listed below.

1. Select a reamer with a diameter of curvature (DOC) that is slightly greater than that of the humeral head (a diameter mismatch of 2 mm is commonly used [e.g., a 58-mm DOC reamer with a 56-mm DOC humeral head or a 54-mm DOC reamer with a 52-mm DOC humeral head]). The outer circumference of the reamer needs to be large enough so that the available glenoid surface can be completely reamed. Appropriately sized reamers are not part of a standard total shoulder arthroplasty set.
2. Remove any residual glenoid articular cartilage, typically on the anterior glenoid surface.
3. Burr down the osseous ridge between the anterior and posterior glenoid concavities.
4. Identify the starting point for reamer positioning, which is usually at the center of the glenoid.
5. Drill a hole for a nubbed reamer (or place a guidewire) in the glenoid center.
6. Use 1 of 2 methods to orient the glenoid reamer:
 - a. Insert a nubbed reamer into a hole at the glenoid center and iteratively adjust the orientation of the reamer to create a single concavity while removing the least amount of bone (the end point is when the reamer contacts the entire glenoid surface).
 - b. Insert a cannulated reamer over a guidewire that is inserted at an angle that is determined by 3-dimensional preoperative planning.
7. Burr any remaining prominences or ream lines.
8. Ensure that the reamed surface is smooth and monoconcave.
9. Additional options include:
 - a. Harvest a plug of bone from the resected humeral head

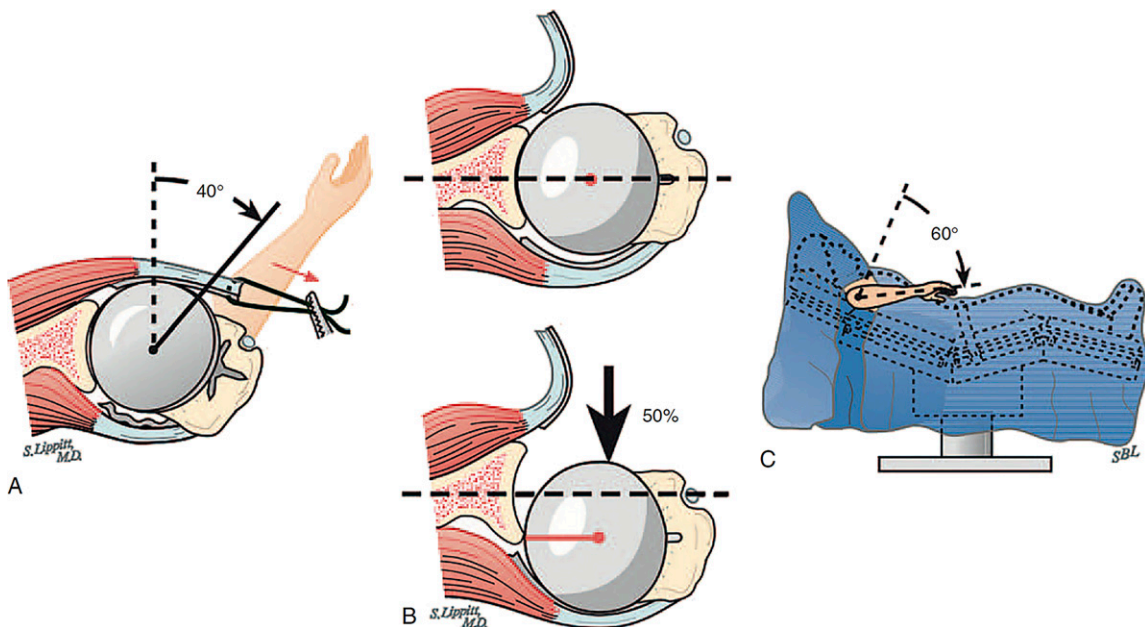


Fig. 3

Figs. 3-A, 3-B, and 3-C The 40-50-60 guidelines. An RnR arthroplasty is well balanced if the shoulder allows at least 150° of passive elevation and if (A) the shoulder allows 40° of external rotation with the subscapularis approximated to its reattachment site, (B) the humeral head can be manually translated by 50% of the glenoid width, and (C) the abducted arm can be internally rotated 60°. (Reproduced, with permission, from: Rockwood C, Wirth M, Fehring E. Rockwood and Matsen's The Shoulder. Matsen F, Sperling J, Lippitt S, editors. 5th ed. Elsevier; 2016.)

with a trephine and, after reaming is complete, insert it flush into the hole that was used to center the glenoid reamer.

- b. Drill multiple holes in the sclerotic glenoid surface.

The Humeral Component

The RnR procedure requires secure humeral component fixation with maximal bone preservation and minimal risk of fracture. A common technique is to use a smooth, relatively narrow standard-length stem that is fixed with impaction autografting^{42,43}. Without removing diaphyseal endosteal bone, this approach provides a low canal-filling ratio with minimal risk of stress-shielding⁴², facilitates stem positioning, and leaves open the possibility of plate fixation if a periprosthetic fracture occurs. Other humeral implant options include a short stem that is press-fit into the proximal canal with or without porous ingrowth surfaces or a stemless humeral component. The former avoids the diaphysis but may be associated with increased risk of stress-shielding, varus or valgus stem malpositioning, and difficulties in treating a periprosthetic fracture. The latter avoids the canal and may facilitate optimal head placement on the cut surface but may risk a non-anatomic humeral head cut and suboptimal fixation if the metaphyseal bone is soft.

The prosthetic humeral head has 3 important dimensions: the DOC, the thickness, and the presence or absence of an offset (eccentricity) that can be used to modify the anteroposterior position of the articular surface. The DOC affects the glenohumeral contact area, the thickness affects the soft-tissue balance, and the offset can be used to manage posterior instability without overstuffing of the joint³². Some surgeons prioritize restoring glenohumeral anatomy, while others consider increasing the DOC of the prosthetic humeral head, decreasing the thickness of the head, and using anteriorly eccentric components to optimize the balance

between mobility and stability⁴⁴ (see Appendix, Case 1).

Regardless of the selection of the prosthesis dimensions and fixation method, the prosthetic head should remain centered on the reamed glenoid throughout the range of motion, including at $>150^\circ$ of flexion. The “40-50-60” rules are helpful in establishing proper balance of the arthroplasty: the mobilized subscapularis tendon should reach the insertion site with the arm in 40° of external rotation, the trial humeral head should be posteriorly translatable for 50% of the width of the glenoid, and there should be 60° of internal rotation with the arm abducted to 90° (Fig. 3). It is important to check for unwanted contact between the proximal humeral bone and the glenoid when the arm is adducted or externally rotated.

Avoiding Posterior Decentering

Stability of the arthroplasty is optimized by reaming to a single glenoid concavity and by soft-tissue balancing. Correcting retroversion does not appear to be necessary to achieve stability of the RnR. The prosthetic head must not be seated superiorly in relation to the neck cut since that positioning may increase the risk of posterior instability when the arm is flexed. If there is excessive posterior translation of the humeral head, an anteriorly eccentric head component may be preferable to increasing the component's thickness⁴⁴ (Fig. 1-B).

Once the definitive humeral component is inserted, the 40-50-60 tests are repeated. If the balance of the shoulder is appropriate, the subscapularis tendon is repaired. If excessive posterior translation remains at this point in the procedure, a rotator interval plication (approximating the superior edge of the subscapularis to the anterior edge of the supraspinatus) can be performed (Fig. 4). The stabilizing effect is greater when more sutures are used and when they are placed more medially. Excessive plication can lead to stiffness of the shoulder.

Postoperative instability of the RnR is uncommon and, if it occurs, can

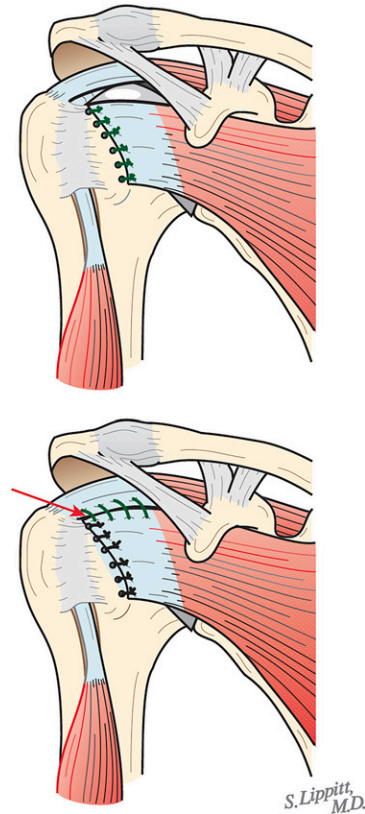


Fig. 4

The rotator interval plication. If the arthroplasty demonstrates instability after the subscapularis has been repaired, stability can be achieved by approximating the superior edge of the subscapularis to the anterior edge of the supraspinatus, starting laterally (red arrow). Increasing the number of medial sutures increases the tightness of the shoulder. Because this is a powerful technique, surgeons need to avoid stiffness from overtightening. (Reproduced, with permission, from: Rockwood C, Wirth M, Fehring E. Rockwood and Matsen's The Shoulder. Matsen F, Sperling J, Lippitt S, editors. 5th ed. Elsevier; 2016.)

usually be managed by rehabilitating the shoulder with elevation posterior to the scapular plane and by strengthening the external rotators.

Rehabilitation and Recovery

Rehabilitation after the RnR is more demanding than that after a TSA. Range-of-motion exercises are started on the day of surgery, with a focus on achieving the desired motion before the patient leaves the medical center. For the first 6 weeks, the priority is to maintain $>150^\circ$ of assisted elevation while avoiding excessive external

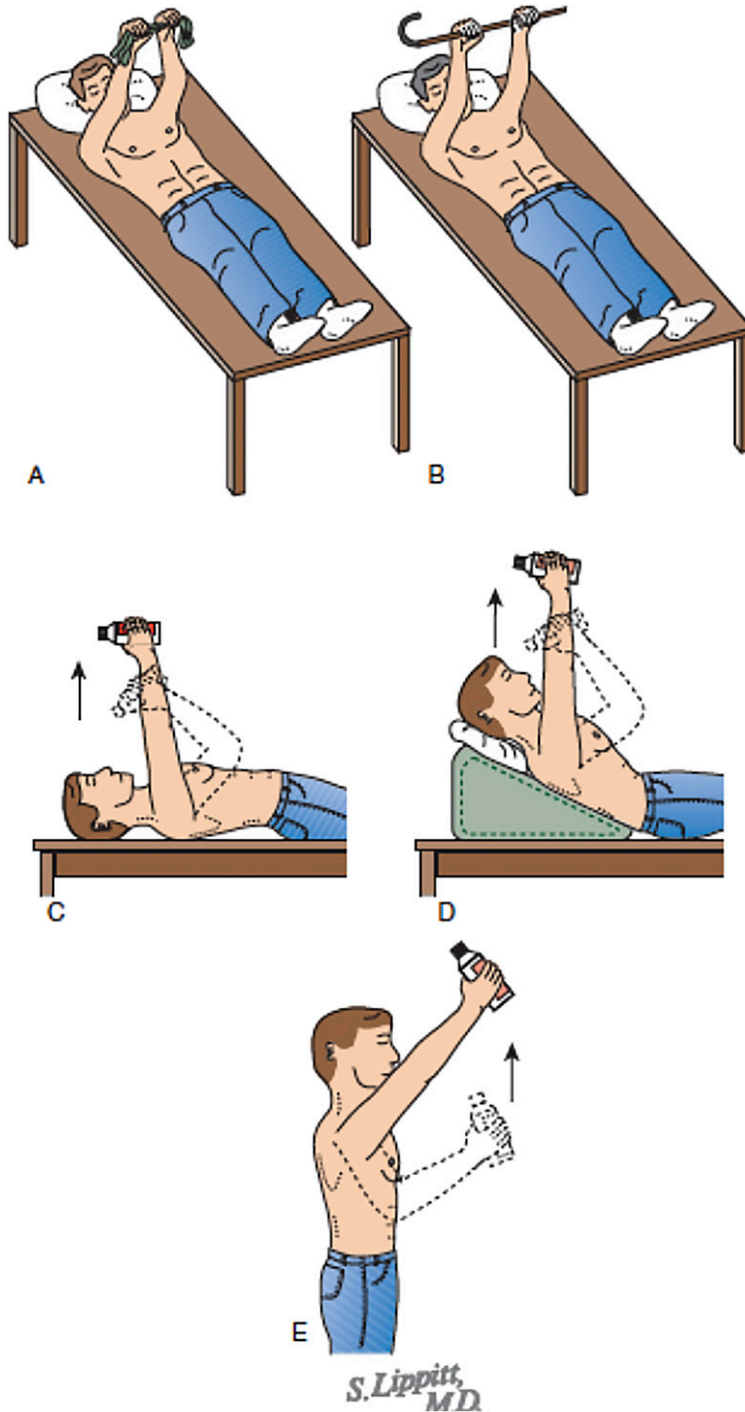


Fig. 5

Figs. 5-A through 5-E The progressive press-up exercise. An effective and safe rehabilitation program for regaining strength after an RnR procedure is typically started at 6 weeks after surgery. **Fig. 5-A** The program starts with an assisted press-up with the hands close together, with the unoperated arm providing the necessary assistance. **Fig. 5-B** As the operated shoulder gets stronger, the hands are increasingly separated. **Fig. 5-C** The next step is the single-hand supine press-up using a light weight. When this exercise can be repeated comfortably, the chest is progressively inclined (**Fig. 5-D**) until the exercise can be performed in the standing position (**Fig. 5-E**). In each exercise, the scapula is protracted to help retrain the scapular stabilizers (the “press plus”). Twenty comfortable repetitions need to be achieved before advancing to the next level (the rule of 20). (Reproduced, with permission, from: Rockwood C, Wirth M, Fehring E. Rockwood and Matsen’s The Shoulder. Matsen F, Sperling J, Lippitt S, editors. 5th ed. Elsevier; 2016.)

rotation stretching in order to protect the subscapularis repair²⁶. Three exercises are useful in this regard: the supine stretch, the pulley stretch, and the forward-lean table slide⁴⁵. The latter 2 are particularly useful for patients with a compromised contralateral shoulder.

At 2 weeks postoperatively, stretching in abduction, internal rotation, and cross-body adduction is added. During the early phases of rehabilitation, patients may experience a sensation of minor translation during the range-of-motion exercises. This is managed by reassurance and external rotation isometrics.

At 6 weeks postoperatively, gentle progressive strengthening is started using the 2-hand supine press-up while holding a yardstick or a dowel in both hands. This is transitioned to a 1-hand press-up with a 1-lb (0.45-kg) weight. As this becomes easier, the patients adjust their position so that their chest is progressively inclined to

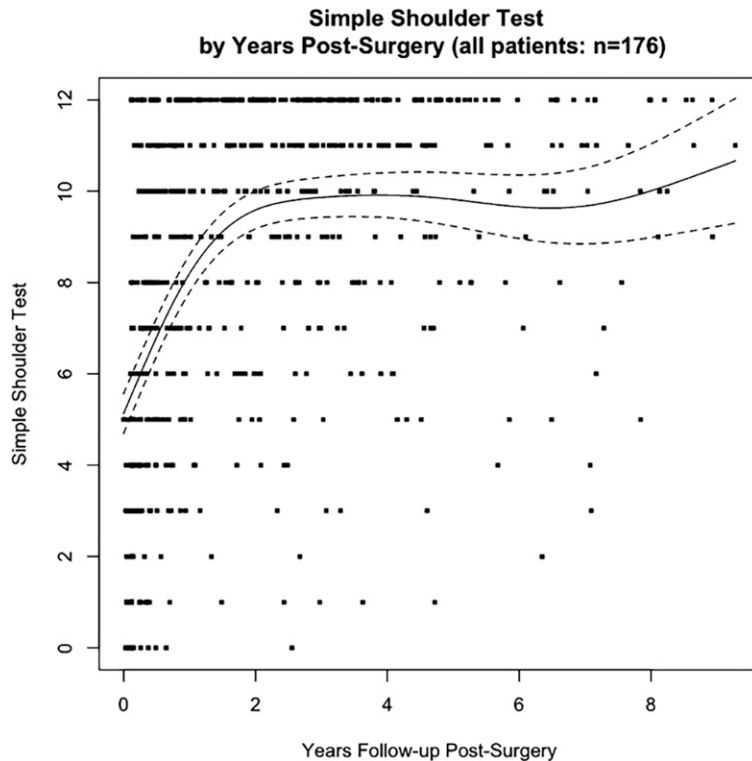


Fig. 6

RnR outcome. The mean (and 95% confidence interval) Simple Shoulder Test (SST) scores are shown before and sequentially after the procedure. For most of the patients who are selected for this procedure, the RnR can provide durable improvement in patient self-assessed comfort and function; however, as shown in the lower right-hand quadrant, some patients fail to achieve the desired outcome. As shown, 17 of the 176 patients in this early series did not achieve an SST score of ≥ 5 at a minimum of 2 years after surgery. A total of 25 of the 176 patients did not achieve an SST score of ≥ 6 at a minimum of 2 years after surgery. (Reproduced from *The Journal of Bone & Joint Surgery*: Gilmer BB, Comstock BA, Jette, JL, Warne WJ, Jackins SE, and Matsen FA, 3rd. The prognosis for improvement in comfort and function after the ream-and-run arthroplasty for glenohumeral arthritis. An analysis of 176 consecutive cases. 2012;94:e102[1-9], Figure 1.)

a more vertical position (Fig. 5). All of the strengthening exercises are performed with a high number of repetitions (>20) and only to the extent that permits comfort. At this time, gentle low rows, easy pull-downs, and gentle water exercises can be started as tolerated.

It should be noted that some patients experience substantial weakness in the first 2 to 3 months following an RnR procedure. While the cause of this weakness is not clear, it almost always resolves with gently progressive strengthening exercises. At 3 months, general strengthening is started with a focus on the scapular motor control and progressive rotator cuff strengthening. Full recovery of motion and strength requires persistent efforts over the course of a year and beyond.

The Issue of Glenoid Wear

When glenohumeral osteoarthritis is treated by hemiarthroplasty alone, the arthritic glenoid is at risk for progressive erosion, particularly in shoulders with a posterior biconcavity. When an isolated humeral head replacement is used

in a shoulder with a biconcavity, the joint pressure (joint force/surface area) remains concentrated on the pathologic posterior concavity, favoring ongoing wear^{46,47}. By contrast, in the RnR procedure, the biconcave glenoid is converted to a single concentric concavity so that the joint forces are distributed over the maximal area, resulting in lower joint pressure.

In most cases, glenoid wear after an RnR procedure is small (averaging <1 mm/year)⁴⁸⁻⁵⁰. While some medialization may occur early on, wear appears to stop once the reamed glenoid has had the opportunity to heal with a durable sclerotic base supporting the joint surface⁵¹. Factors that may increase the risk of wear include diagnoses that are associated with soft glenoid bone (rheumatoid arthritis, chondrolysis, osteoporosis, steroid arthropathy, and post-infectious arthropathy), valgus positioning of the humeral component⁵², inadequate reaming that does not fully address the biconcavity, and excessive reaming into the subchon-

dral bone⁵¹. Progressive medial wear after an RnR procedure may be a sign of CPJI. Superior wear may be associated with rotator cuff deficiency.

The Issue of Postoperative Stiffness

Factors predisposing to stiffness include preoperative stiffness or instability, diabetes, Parkinson disease, prior surgery (e.g., rotator cuff, SLAP [superior labral anterior-posterior] tears, or instability repair), large shoulder musculature, insufficient preoperative education for the patient by the surgeon, and low patient motivation and resilience²⁵.

At the time of surgery, the risk of postoperative stiffness is reduced by capsular release, subscapularis mobilization, avoiding overstuffing of the joint with too large a humeral head component, avoiding varus positioning of the component stem, and ensuring that the 40-50-60 rules have been met³². A lateral photograph of the patient immediately after surgery with the arm in full flexion can be used to demonstrate that a substantial range of motion has been achieved.

TABLE I Summary of Published Reports on the Ream-and-Run Procedure*

Procedure	No. of Shoulders	Average Age (yr)	Male Sex (%)	Follow-up (mo)	MUA (%)	Surgical Revision (non-aTSA) (%)	Conversion to aTSA (%)	Preop. SST Score	Final SST Score	Preop. ASES Score	Final ASES Score	Preop. Flexion (deg)	Final Flexion (deg)	Return to Sport (%)	Return to Work (%)	Wear (mm/yr)
Clinton et al. (2007) ¹⁶	RnR	35	56	91	28			4.5	9.5							
	aTSA	35	56	91	31			4	10							
Lynch et al. (2007) ⁶¹	RnR	37	57	91	32		3	4.7	9.4			60	138			
Clinton et al. (2009) ³⁸	RnR	189				2	3	5								
Mercer et al. (2011) ⁴⁸	RnR	14	59	79	41											0.40
Saltzman et al. (2011) ⁶²	RnR	65	48	91	44	14	14	4.1	9.5							0.30
Gilmer et al. (2012) ²⁶	RnR	124	57	9	54	3	12	6	4	10						
Matsen et al. (2015) ³⁰	RnR	28	56	96	36		7	5	10							
Somerson and Wirth (2015) ⁵⁰	RnR	17	55	65	47		18	3.4	10	43	90					
Getz et al. (2017) ⁵⁸	RnR	21	50	100	44		25	13	10.4							
Somerson and Matsen (2017) ⁶³	RnR	111	60	95	120	13	6	3	4.9	10.3						0.24
Virk et al. (2018) ⁶⁴	RnR	23	54	90	37		4	6.2	9.9	45	85	115	139			
	aTSA	23	54	91	46			5.6	9.9	46	85	113	154			
Matsen et al. (2019) ²⁷	RnR	263	58	92	24	8	4	1	4.9	10						
	aTSA	281	67	47	24	2	2	2.9	9.5							
Garcia et al. (2019) ⁵⁷	RnR	26	53.1	92	69		4	8		48	84.8			94.4		0.42
	aTSA	30	53.6	90	70		3	3		42.2	83.1			86.4		0.38
Gowd et al. (2019) ⁵⁹	RnR	25	52.8	92	69		4	8		49	84.9				100	
	aTSA	28	53.3	89	69		4	4		44	85.5				89.3	
Schiffman et al. (2020) ³⁴	RnR	295	58	92	24	7	9	4.9	10.1							
	aTSA	345	66	48	24	2	3	2.8	9.4							

*MUA = manipulation under anesthesia, aTSA = anatomic total shoulder arthroplasty, SST = Simple Shoulder Test, ASES = American Shoulder and Elbow Surgeons, and RnR = ream and run.

When the patient has recovered from anesthesia, the surgeon and the therapist implement patient-conducted stretching, motivating the patient by assuring that this will not damage the repair and that the motion that is achieved on the evening of surgery is an approximation of the end result.

After discharge, the surgeon and the patient reestablish the rehabilitation plan, including a home program with or without supervised physical therapy and with ongoing support and close monitoring of the range of flexion. For patients who live at a distance from the medical center, the surgeon can monitor

progress with sequential lateral photographs or videos of the shoulder taken during assisted supine elevation that are sent by email. An MUA with temporary muscle paralysis is considered at 6 to 12 weeks for shoulders that are unable to maintain the range of motion that had been achieved at surgery. The MUA consists of gentle flexion in internal rotation, abduction, and cross-body adduction, avoiding stretching in rotation that might jeopardize the subscapularis repair.

There are 2 types of refractory shoulder stiffness seen after an RnR. In type 1, the shoulder has never achieved

the desired motion. In type 2, the shoulder had achieved an excellent initial range of motion but had become stiff and painful after a “honeymoon” period of good function that lasted for months or even years after surgery.

The common causes of type-1 stiffness are overstuffing of the joint³², excessive rotator interval plication, or lack of adequate rehabilitation. Treatments to consider include more aggressive physical therapy; MUA; arthroscopic capsular release⁵³; or open revision with capsular release, subscapularis mobilization, and re-repair; as well as downsizing of the humeral

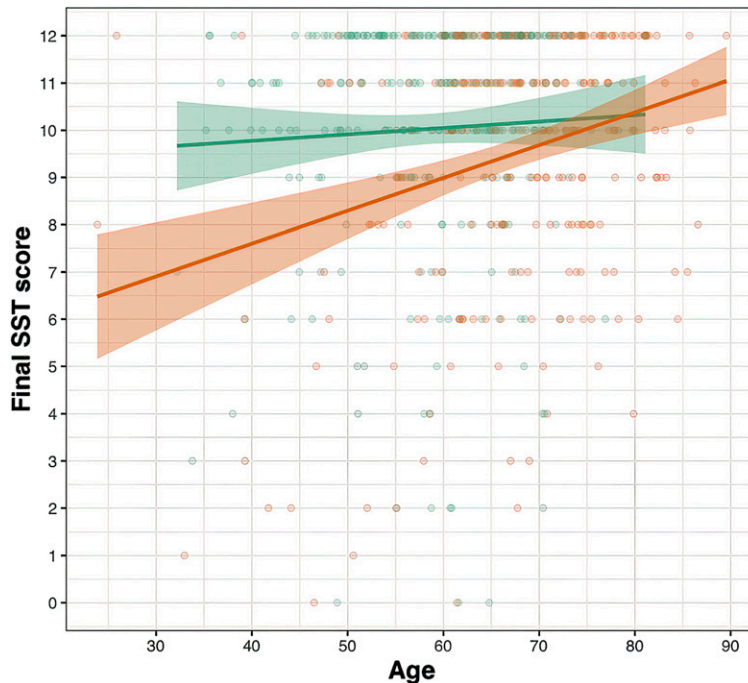


Fig. 7

RnR and total shoulder outcomes by patient age. The 2-year outcomes (2-year Simple Shoulder Test [SST]) for the RnR procedure (upper regression line and 95% confidence interval) are essentially independent of patient age and are not worse for older patients. This is in contrast to the corresponding outcomes for aTSA (lower regression line and 95% confidence interval), which are worse for younger patients. (Reproduced with permission from *International Orthopaedics*: Matsen FA, 3rd, Whiston A, Jackins SE, Neradilek MB, Warme WJ, and Hsu JE. Ream and run and total shoulder: patient and shoulder characteristics in five hundred forty-four concurrent cases. Epub 25 June 2019. Figure 7.)

component with or without re-reaming of the glenoid. Conversion to aTSA is an option if the patient does not wish to continue to pursue the RnR.

CPJI is an important cause of type-2 stiffness. Concern about CPJI is heightened if radiographs show glenoid osteopenia rather than the expected sclerotic remodeling of the joint surface and if there is osteolysis of the proximal medial humerus. Blood cell counts, erythrocyte sedimentation rate, C-reactive protein level, and joint aspiration have limited utility in excluding the possibility of CPJI. In this circumstance, surgeons may consider a single-stage prosthesis exchange after vigorous irrigation and debridement, followed by an initial course of intravenous antibiotics that are modified according to the results of the intraoperative culture specimens^{54,55}.

Outcomes

Patients and surgeons arrive at the decision to perform an RnR after careful consideration of the goals and characteristics of the patient as well as the pathoanatomy of the shoulder. The selection process differs among surgeons: some may choose only “perfect”

candidates, whereas others may offer the RnR procedure, believing that no other procedure should be considered for the patient and the pathology (e.g., a severe type-B2 glenoid in a highly active patient). As a result, the outcome of the procedure may be strongly influenced by the status of the patient and the shoulder prior to surgery: patients with higher levels of function before surgery are more likely to be satisfied with their outcomes postoperatively²⁶. Many patients having the RnR procedure have levels of postoperative function that are equal to or better than those for aTSA^{16,23,26,27,30,34,38,48,50,51,56-64} (Fig. 6, Table I). Three example cases are presented in the Appendix (Case 1, Case 2, and Case 3).

Factors that are associated with an increased risk of poor outcomes include poor preoperative function, prior shoulder surgery, narcotic use, female sex, and smoking. Older patients who undergo the RnR procedure appear to fare equally well in comparison with younger patients (Fig. 7). The comfort and function of patients struggling with stiffness after the RnR procedure often can be restored by MUA or downsizing the thickness of the humeral head

combined with soft-tissue releases, yielding a satisfactory end result. A substantial number of RnR failures appear to be due to CPJI, which is of particular concern in the RnR demographic. In most cases, CPJI can be effectively managed with a single-stage exchange⁵⁴.

While there was a relatively high degree of consensus among the 11 surgeons who are represented in this review article, there was also diversity of opinion on some of the critical aspects of the RnR procedure (see Appendix, Consensus Table). Much remains to be learned about how the outcomes of the RnR procedure can be optimized. Below are some of the major questions that need to be addressed:

1. What is the best way to assess the long-term outcome of the RnR procedure?
2. Can the risk of failure from postoperative stiffness be reduced by accepting greater joint laxity at the time of the RnR procedure?
3. How does the long-term durability of the RnR procedure compare with aTSA?
4. How do the radiographic changes after the RnR procedure (e.g.,

formation of a soft-tissue layer, extent of glenoid wear, and glenoid bone density) correlate with the outcome?

5. Will current methods of prophylaxis against CPJI result in lower rates of infection and better long-term outcomes?
6. How can we minimize failures of the RnR procedure that are due to a lack of understanding of or improper adherence to the established principles and techniques?

Appendix

Supporting material provided by the authors is posted with the online version of this article as a data supplement at <http://links.lww.com/JBJSREV/A739>.

NOTE: The authors thank Susan DeBartolo (University of Washington Department of Orthopaedics and Sports Medicine) for her editorial work on the manuscript and Steven B. Lippitt (Akron General Orthopaedics) for his artwork in the figures. Thanks also to the other senior authors who have contributed to our knowledge on the ream-and-run procedure, including Jeremy Somerson, Brian Gilmer, Joseph Lynch, Jeremiah Clinton, Anthony Romeo, and Gerald Williams. Finally, we thank Sarah Jackins, RPT, for her decades of work in pursuit of the optimal rehabilitation program for individuals having the ream-and-run procedure and for sharing her knowledge with all of us.

Frederick A. Matsen III, MD¹,
Bradley C. Carofino, MD²,
Andrew Green, MD³,
Samer S. Hasan, MD, PhD⁴,
Jason E. Hsu, MD¹,
Mark D. Lazarus, MD⁵,
Matthew D. McElvany, MD, MAS⁶,
Michael J. Moskal, MD⁷,
I. Moby Parsons IV, MD⁸,
Matthew D. Saltzman, MD⁹,
Winston J. Warme, MD¹

¹Department of Orthopaedics and Sports Medicine, University of Washington, Seattle, Washington

²Atlantic Orthopaedic Specialists, Virginia Beach, Virginia

³Department of Orthopaedic Surgery, Warren Alpert Medical School of Brown University, East Providence, Rhode Island

⁴Mercy Health-Cincinnati SportsMedicine and Orthopaedic Center, Cincinnati, Ohio

⁵Department of Orthopaedics, The Rothman Orthopaedic Institute, Philadelphia, Pennsylvania

⁶Department of Orthopaedics, The Permanente Medical Group, Santa Rosa, California

⁷Shoulder & Elbow Center, P.S.C., Sellersburg, Indiana

⁸The Knee, Hip and Shoulder Center, Portsmouth, New Hampshire

⁹Department of Orthopaedic Surgery, Northwestern University Feinberg School of Medicine, Chicago, Illinois

Email for corresponding author:
matsen@uw.edu

References

1. Clement ND, Duckworth AD, Colling RC, Stirrat AN. An uncemented metal-backed glenoid component in total shoulder arthroplasty for osteoarthritis: factors affecting survival and outcome. *J Orthop Sci.* 2013 Jan;18(1):22-8. Epub 2012 Sep 26.
2. Denard PJ, Raiss P, Sowa B, Walch G. Mid- to long-term follow-up of total shoulder arthroplasty using a keeled glenoid in young adults with primary glenohumeral arthritis. *J Shoulder Elbow Surg.* 2013 Jul;22(7):894-900. Epub 2013 Jan 9.
3. Hasan SS, Leith JM, Campbell B, Kapil R, Smith KL, Matsen FA 3rd. Characteristics of unsatisfactory shoulder arthroplasties. *J Shoulder Elbow Surg.* 2002 Sep-Oct;11(5):431-41.
4. Hsu JE, Hackett DJ Jr, Vo KV, Matsen FA 3rd. What can be learned from an analysis of 215 glenoid component failures? *J Shoulder Elbow Surg.* 2018 Mar;27(3):478-86. Epub 2018 Jan 5.
5. McLendon PB, Schoch BS, Sperling JW, Sánchez-Sotelo J, Schleck CD, Cofield RH. Survival of the pegged glenoid component in shoulder arthroplasty: part II. *J Shoulder Elbow Surg.* 2017 Aug;26(8):1469-76. Epub 2017 Feb 1.
6. Neyton L, Kirsch JM, Collotte P, Collin P, Gossing L, Chelli M, Walch G. Mid- to long-term follow-up of shoulder arthroplasty for primary glenohumeral osteoarthritis in patients aged 60 or under. *J Shoulder Elbow Surg.* 2019 Sep;28(9):1666-73. Epub 2019 Jun 13.
7. Papadonikolakis A, Neradilek MB, Matsen FA 3rd. Failure of the glenoid component in anatomic total shoulder arthroplasty: a systematic review of the English-language literature between 2006 and 2012. *J Bone Joint Surg Am.* 2013 Dec 18;95(24):2205-12.
8. Raiss P, Aldinger PR, Kasten P, Rickert M, Loew M. Total shoulder replacement in young and middle-aged patients with glenohumeral osteoarthritis. *J Bone Joint Surg Br.* 2008 Jun;90(6):764-9.
9. Roberson TA, Bentley JC, Griscom JT, Kissenberth MJ, Tolan SJ, Hawkins RJ, Tokish JM. Outcomes of total shoulder arthroplasty in patients younger than 65 years: a systematic review. *J Shoulder Elbow Surg.* 2017 Jul;26(7):1298-306. Epub 2017 Feb 10.
10. Somerson JS, Hsu JE, Neradilek MB, Matsen FA 3rd. Analysis of 4063 complications of shoulder arthroplasty reported to the US Food and Drug Administration from 2012 to 2016. *J Shoulder Elbow Surg.* 2018 Nov;27(11):1978-86. Epub 2018 May 11.
11. Walch G, Young AA, Boileau P, Loew M, Gazielly D, Molé D. Patterns of loosening of polyethylene keeled glenoid components after shoulder arthroplasty for primary osteoarthritis: results of a multicenter study with more than five years of follow-up. *J Bone Joint Surg Am.* 2012 Jan 18;94(2):145-50.
12. Young A, Walch G, Boileau P, Favard L, Gohlke F, Loew M, Molé D. A multicentre study of the long-term results of using a flat-back polyethylene glenoid component in shoulder replacement for primary osteoarthritis. *J Bone Joint Surg Br.* 2011 Feb;93(2):210-6.
13. Brolin TJ, Thakar OV, Abboud JA. Outcomes after shoulder replacement surgery in the young patient: How do they do and how long can we expect them to last? *Clin Sports Med.* 2018 Oct;37(4):593-607.
14. Padegimas EM, Maltenfort M, Lazarus MD, Ramsey ML, Williams GR Jr, Namdari S. Future patient demand for shoulder arthroplasty by younger patients: national projections. *Clin Orthop Relat Res.* 2015 Jun;473(6):1860-7. Epub 2015 Mar 11.
15. Saltzman MD, Mercer DM, Warme WJ, Bertelsen AL, Matsen FA 3rd. Comparison of patients undergoing primary shoulder arthroplasty before and after the age of fifty. *J Bone Joint Surg Am.* 2010 Jan;92(1):42-7.
16. Clinton J, Franta AK, Lenters TR, Mounce D, Matsen FA 3rd. Nonprosthetic glenoid arthroplasty with humeral hemiarthroplasty and total shoulder arthroplasty yield similar self-assessed outcomes in the management of comparable patients with glenohumeral arthritis. *J Shoulder Elbow Surg.* 2007 Sep-Oct;16(5):534-8. Epub 2007 May 16.
17. Harryman DT 2nd, Sidles JA, Clark JM, McQuade KJ, Gibb TD, Matsen FA 3rd. Translation of the humeral head on the glenoid with passive glenohumeral motion. *J Bone Joint Surg Am.* 1990 Oct;72(9):1334-43.
18. Matsen FA 3rd, Bicknell RT, Lippitt SB. Shoulder arthroplasty: the socket perspective. *J Shoulder Elbow Surg.* 2007 Sep-Oct;16(5)(Suppl):S241-7. Epub 2007 Apr 19.
19. Matsen FA 3rd, Whitson A, Hsu JE, Stankovic NK, Neradilek MB, Somerson JS. Prearthroplasty glenohumeral pathoanatomy and its relationship to patient's sex, age, diagnosis, and self-assessed shoulder comfort and function. *J Shoulder Elbow Surg.* 2019 Dec;28(12):2290-300. Epub 2019 Jul 13.
20. Weldon EJ 3rd, Boorman RS, Smith KL, Matsen FA 3rd. Optimizing the glenoid contribution to the stability of a humeral hemiarthroplasty without a prosthetic glenoid. *J Bone Joint Surg Am.* 2004 Sep;86(9):2022-9.

- 21.** Matsen FA 3rd, Clark JM, Titelman RM, Gibbs KM, Boorman RS, Deffenbaugh D, Korvick DL, Norman AG, Ott SM, Parsons IM 4th, Sidles JA. Healing of reamed glenoid bone articulating with a metal humeral hemiarthroplasty: a canine model. *J Orthop Res.* 2005 Jan;23(1):18-26.
- 22.** Matsen FA 3rd. The ream and run: not for every patient, every surgeon or every problem. *Int Orthop.* 2015 Feb;39(2):255-61. Epub 2015 Jan 24.
- 23.** Matsen FA 3rd, Russ SM, Vu PT, Hsu JE, Lucas RM, Comstock BA. What factors are predictive of patient-reported outcomes? A prospective study of 337 shoulder arthroplasties. *Clin Orthop Relat Res.* 2016 Nov;474(11):2496-510. Epub 2016 Jul 25.
- 24.** Somerson JS, Hsu JE, Neradilek MB, Matsen FA 3rd. The "tipping point" for 931 elective shoulder arthroplasties. *J Shoulder Elbow Surg.* 2018 Sep;27(9):1614-21. Epub 2018 May 7.
- 25.** Vranceanu AM, Reichman M, Mace RA, Mohamadi A, Chen N. Does a patient's approach to achieving goals influence his or her recovery trajectory after musculoskeletal illness? *Clin Orthop Relat Res.* 2020 Sep;478(9):2067-76.
- 26.** Gilmer BB, Comstock BA, Jette JL, Warme WJ, Jackins SE, Matsen FA 3rd. The prognosis for improvement in comfort and function after the ream-and-run arthroplasty for glenohumeral arthritis: an analysis of 176 consecutive cases. *J Bone Joint Surg Am.* 2012 Jul 18;94(14):e102.
- 27.** Matsen FA 3rd, Whitson A, Jackins SE, Neradilek MB, Warme WJ, Hsu JE. Ream and run and total shoulder: patient and shoulder characteristics in five hundred forty-four concurrent cases. *Int Orthop.* 2019 Sep;43(9):2105-15. Epub 2019 Jun 25.
- 28.** Luedke C, Kissenberth MJ, Tolan SJ, Hawkins RJ, Tokish JM. Outcomes of anatomic total shoulder arthroplasty with B2 glenoids: A systematic review. *JBJS Rev.* 2018 Apr;6(4):e7.
- 29.** Shanmugaraj A, Sarraj M, Coughlin RP, Guerrero EM, Ekhtiari S, Ayeni OR, Garrigues GE. Surgical management of glenohumeral osteoarthritis with glenoid erosion and static posterior subluxation (Walch B2): techniques, outcomes, and survivorship rates. *Orthopedics.* 2020 Jul 1;43(4):e191-201. Epub 2020 Apr 23.
- 30.** Matsen FA 3rd, Warme WJ, Jackins SE. Can the ream and run procedure improve glenohumeral relationships and function for shoulders with the arthritic triad? *Clin Orthop Relat Res.* 2015 Jun;473(6):2088-96. Epub 2014 Dec 9.
- 31.** Matsen FA 3rd, Gupta A. Axillary view: arthritic glenohumeral anatomy and changes after ream and run. *Clin Orthop Relat Res.* 2014 Mar;472(3):894-902. Epub 2013 Oct 18.
- 32.** Matsen FA 3rd, Lippitt SB, Sidles JA, Harryman DT 2nd. Practical evaluation and management of the shoulder. 1st ed. Philadelphia: W. B. Saunders Company; 1994. Smoothness; p 181-92.
- 33.** Matsen FA 3rd, Whitson A, Neradilek MB, Pottinger PS, Bertelsen A, Hsu JE. Factors predictive of Cutibacterium periprosthetic shoulder infections: a retrospective study of 342 prosthetic revisions. *J Shoulder Elbow Surg.* 2020 Jun;29(6):1177-87. Epub 2019 Oct 24.
- 34.** Schiffman CJ, Hannay WM, Whitson AJ, Neradilek MB, Matsen FA 3rd, Hsu JE. Impact of previous non-arthroplasty surgery on clinical outcomes after primary anatomic shoulder arthroplasty. *J Shoulder Elbow Surg.* 2020 Oct;29(10):2056-64. Epub 2020 Apr 22.
- 35.** Matsen FA 3rd, Whitson AJ, Pottinger PS, Neradilek MB, Hsu JE. Cutaneous microbiology of patients having primary shoulder arthroplasty. *J Shoulder Elbow Surg.* 2020 Aug;29(8):1671-80. Epub 2020 Apr 1.
- 36.** Hsu JE, Whitson AJ, Woodhead BM, Napierala MA, Gong D, Matsen FA 3rd. Randomized controlled trial of chlorhexidine wash versus benzoyl peroxide soap for home surgical preparation: neither is effective in removing Cutibacterium from the skin of shoulder arthroplasty patients. *Int Orthop.* 2020 Jul;44(7):1325-9. Epub 2020 May 8.
- 37.** Matsen FA 3rd, Whitson AJ, Hsu JE. While home chlorhexidine washes prior to shoulder surgery lower skin loads of most bacteria, they are not effective against Cutibacterium (Propionibacterium). *Int Orthop.* 2020 Mar;44(3):531-4. Epub 2020 Jan 14.
- 38.** Clinton J, Warme WJ, Lynch JR, Lippitt SB, Matsen FA 3rd. Shoulder hemiarthroplasty with nonprosthetic glenoid arthroplasty: the ream and run. *Tech Shoulder Elbow Surg.* 2009 Mar;10(1):43-52.
- 39.** Matsen FA 3rd, Lippitt SB. Current technique for the ream-and-run arthroplasty for glenohumeral osteoarthritis. *JBJS Essent Surg Tech.* 2012 Oct 10;2(4):e20.
- 40.** Matsen FA 3rd. Ream & run humeral hemiarthroplasty. *Video Journal of Orthopaedics.* 2009 Sep. Accessed October 3, 2020. <https://www.vjortho.com/2009/09/ream-run-humeral-hemiarthroplasty/>
- 41.** Olson S, Clinton JM, Working Z, Lynch JR, Warme WJ, Womack W, Matsen FA 3rd. Thermal effects of glenoid reaming during shoulder arthroplasty in vivo. *J Bone Joint Surg Am.* 2011 Jan 5;93(1):11-9.
- 42.** Denard PJ, Hsu JE, Whitson A, Neradilek MB, Matsen FA 3rd. Radiographic outcomes of impaction-grafted standard-length humeral components in total shoulder and ream-and-run arthroplasty: is stress shielding an issue? *J Shoulder Elbow Surg.* 2019 Nov;28(11):2181-90. Epub 2019 Jul 2.
- 43.** Lucas RM, Hsu JE, Gee AO, Neradilek MB, Matsen FA 3rd. Impaction autografting: bone-preserving, secure fixation of a standard humeral component. *J Shoulder Elbow Surg.* 2016 Nov;25(11):1787-94. Epub 2016 Jun 1.
- 44.** Hsu JE, Gee AO, Lucas RM, Somerson JS, Warme WJ, Matsen FA 3rd. Management of intraoperative posterior decentering in shoulder arthroplasty using anteriorly eccentric humeral head components. *J Shoulder Elbow Surg.* 2016 Dec;25(12):1980-8. Epub 2016 Apr 7.
- 45.** Matsen FA 3rd. Shoulder exercises. 2012 Dec 17. Accessed October 10, 2020. <https://shoulderarthriti.blogspot.com/2012/12/shoulder-exercises.html>
- 46.** Levine WN, Djurasovic M, Glasson JM, Pollock RG, Flatow EL, Bigliani LU. Hemiarthroplasty for glenohumeral osteoarthritis: results correlated to degree of glenoid wear. *J Shoulder Elbow Surg.* 1997 Sep-Oct;6(5):449-54.
- 47.** Sperling JW, Cofield RH, Rowland CM. Neer hemiarthroplasty and Neer total shoulder arthroplasty in patients fifty years old or less. Long-term results. *J Bone Joint Surg Am.* 1998 Apr;80(4):464-73.
- 48.** Mercer DM, Gilmer BB, Saltzman MD, Bertelsen A, Warme WJ, Matsen FA 3rd. A quantitative method for determining medial migration of the humeral head after shoulder arthroplasty: preliminary results in assessing glenoid wear at a minimum of two years after hemiarthroplasty with concentric glenoid reaming. *J Shoulder Elbow Surg.* 2011 Mar;20(2):301-7. Epub 2010 Jul 24.
- 49.** Parsons IM 4th, Millett PJ, Warner JJP. Glenoid wear after shoulder hemiarthroplasty: quantitative radiographic analysis. *Clin Orthop Relat Res.* 2004 Apr;421:120-5.
- 50.** Somerson JS, Wirth MA. Self-assessed and radiographic outcomes of humeral head replacement with nonprosthetic glenoid arthroplasty. *J Shoulder Elbow Surg.* 2015 Jul;24(7):1041-8. Epub 2015 Jan 1.
- 51.** Somerson JS, Neradilek MB, Service BC, Hsu JE, Russ SM, Matsen FA 3rd. Clinical and radiographic outcomes of the ream-and-run procedure for primary glenohumeral arthritis. *J Bone Joint Surg Am.* 2017 Aug 2;99(15):1291-304.
- 52.** Hackett DJ Jr, Hsu JE, Matsen FA 3rd. Primary shoulder hemiarthroplasty: what can be learned from 359 cases that were surgically revised? *Clin Orthop Relat Res.* 2018 May;476(5):1031-40.
- 53.** Parker DB, Smith AC, Fleckenstein CM, Hasan SS. Arthroscopic evaluation and treatment of complications that arise following prosthetic shoulder arthroplasty. *JBJS Rev.* 2020 Aug;8(8):e2000020-8.
- 54.** Hsu JE, Gorbaty JD, Whitney IJ, Matsen FA 3rd. Single-stage revision is effective for failed shoulder arthroplasty with positive cultures for Propionibacterium. *J Bone Joint Surg Am.* 2016 Dec 21;98(24):2047-51.
- 55.** Yao JJ, Jurgensmeier K, Woodhead BM, Whitson AJ, Pottinger PS, Matsen FA 3rd, Hsu JE. The Use and Adverse Effects of Oral and Intravenous Antibiotic Administration for Suspected Infection After Revision Shoulder Arthroplasty. *J Bone Joint Surg Am.* 2020 Jun 3;102(11):961-70.
- 56.** Edwards TB. CORR Insights®: Can the Ream and Run Procedure Improve Glenohumeral Relationships and Function for Shoulders With the Arthritic Triad? *Clin Orthop Relat Res.* 2015 Jun;473(6):2097-8. Epub 2015 Jan 9.
- 57.** Garcia GH, Gowd AK, Liu JN, Malaret MR, Cabarcas BC, Romeo AA. Return to sport following hemiarthroplasty with concentric reaming versus total shoulder arthroplasty: a matched pair analysis. *Orthopedics.* 2019 Sep 1;42(5):276-84. Epub 2019 Jul 2.
- 58.** Getz CL, Kearns KA, Padegimas EM, Johnston PS, Lazarus MD, Williams GR Jr. Survivorship of hemiarthroplasty with concentric glenoid reaming for glenohumeral arthritis in young, active patients with a biconcave glenoid. *J Am Acad Orthop Surg.* 2017 Oct;25(10):715-23.
- 59.** Gowd AK, Garcia GH, Liu JN, Malaret MR, Cabarcas BC, Romeo AA. Comparative analysis of work-related outcomes in hemiarthroplasty with concentric glenoid reaming and total shoulder arthroplasty. *J Shoulder Elbow Surg.* 2019 Feb;28(2):244-51. Epub 2018 Sep 27.
- 60.** Hasan SS. Revisiting the Socket: Commentary on an article by Jeremy S. Somerson, MD, et al.: "Clinical and Radiographic Outcomes of the Ream-and-Run Procedure for

Primary Glenohumeral Arthritis". *J Bone Joint Surg Am.* 2017 Aug 2;99(15):e85.

61. Lynch JR, Franta AK, Montgomery WH Jr, Lenters TR, Mounce D, Matsen FA 3rd. Self-assessed outcome at two to four years after shoulder hemiarthroplasty with concentric glenoid reaming. *J Bone Joint Surg Am.* 2007 Jun;89(6):1284-92.

62. Saltzman MD, Chamberlain AM, Mercer DM, Warne WJ, Bertelsen AL, Matsen FA 3rd. Shoulder hemiarthroplasty with concentric glenoid reaming in patients 55 years old or less. *J Shoulder Elbow Surg.* 2011 Jun;20(4):609-15. Epub 2010 Dec 16.

63. Somerson JS, Matsen FA 3rd. Functional outcomes of the ream-and-run shoulder arthro-

plasty: A concise follow-up of a previous report. *J Bone Joint Surg Am.* 2017 Dec 6;99(23):1999-2003.

64. Virk MS, Thorsness RJ, Griffin JW, Kim J, Aiyash S, Malaret M, Romeo AA. Short-term clinical outcomes of hemiarthroplasty with concentric glenoid reaming: The ream and run procedure. *Orthopedics.* 2018 Nov 1;41(6):e854-60. Epub 2018 Oct 29.